

A Case of Gastric Atony on Bulimia Nervosa

Sun Pyo Kim,¹ Seong Jung Kim,¹ Kyung Hoon Sun,¹ and Yongjin Park^{1*}

¹Department of Emergency Medicine, College of Medicine, Chosun University, Gwangju, Republic of Korea

*Corresponding author: Yongjin Park, Department of Emergency Medicine, College of Medicine, Chosun University, 365 Philmun-daero, Dong-gu, Gwangju, Republic of Korea. Tel: +82-622203285, Fax: +82-622243501, E-mail: eryongjin@chosun.ac.kr

Received 2017 March 02; Revised 2017 June 03; Accepted 2017 July 29.

Abstract

Introduction: Bulimia nervosa is a serious, potentially life-threatening eating disorder characterized by a cycle of bingeing and compensatory behaviors such as self-induced vomiting to undo or compensate for the effects of binge eating.

Case Presentation: We present a 24-year-old female patient with severe abdominal pain and distension after binge eating. This patient was admitted to the Chosun University hospital in Gwangju, Republic of Korea, on January 2017. In spite of conservative treatment, the symptoms were more aggravated. Therefore, we decided to conduct operative intervention. After gastrotomy, massive bleeding showed on nasogastric tube and drain site, then disseminated intravascular coagulopathy was developed. On the third postoperative day, the patient died despite of resuscitation.

Conclusions: We should pay attention to gastric atony in bulimia nervosa. Therefore, we must prevent massive gastric dilation, constant gastrointestinal bleeding, and disseminated intravascular coagulopathy.

Keywords: Bulimia Nervosa, Gastric Atony, Disseminated Intravascular Coagulopathy

1. Introduction

Characteristics of bulimia nervosa include repeated binge eating and entailing inappropriate and abnormal compensatory behaviors, such as throwing up by putting one's hand down the throat or with the use of laxatives, and extreme working out. Accurate causes of bulimia are not known but core causes are explained to be loss of stability in youth and adolescence or avoidance of becoming an adult as well as anxiety towards developmental problems one face during late adolescence (1-3). There are significant number of bulimia nervosa patients who overeat and visit the emergency room due to acute stomachache, distension, and vomiting. Early diagnosis of such situation may lead to easy improvement with protective care; but if diagnose is delayed, many complications may occur, and there will be a need for complicated and extensive operations, with delayed improvement.

Gastric dilatation is defined radiographically as a gastric gas pattern clearly observed on radiograph to be larger than the expected size of the entire stomach. The incidence of acute gastric dilatation (AGD) is quite rare compared to other gastric pathologies, with relatively limited references in the literature, most of them as case reports. AGD can have multiple etiologies leading to ischemia of the stomach. The etiologies are lifestyle habits, underlying morbidities, acute necrotizing inflammation, acute vascular insufficiency, and postoperative complications. Without proper timely diagnosis and treatment, potentially fa-

tal events such as gastric perforation, hemorrhage, and other serious complications can occur.

In this case, with the acute gastric atony, a bulimia nervosa patient ate too much food in a short period and visited the hospital mainly due to severe abdominal distension and stomachache. Protective cares did not lead to improvements in symptoms and thus post operational treatment symptoms such as gastric atony and disseminated intravascular coagulopathy brought death within 3 days in the hospital. The following is a report of this case

2. Case Presentation

A 25-year-old female patient failed to be accepted to college for 3 years since 5 years ago and dealt with her stress through eating when she was stressed about her conflict with family. For the last 2 years or so, she threw up food equivalent to 5 servings with digestive and laxative and was diagnosed as bulimia nervosa from a private psychiatry. She lost 10 kg in the past 2 years. Around 10 pm the night before admission, she ate approximately 10 servings at one sitting and experienced acute stomachache, abdominal distension, and difficulty in breathing. She tried taking digestives and enema but the symptoms went on when she was admitted to the emergency room at Chosun University hospital, Gwangju, Republic of Korea, in January 2017.

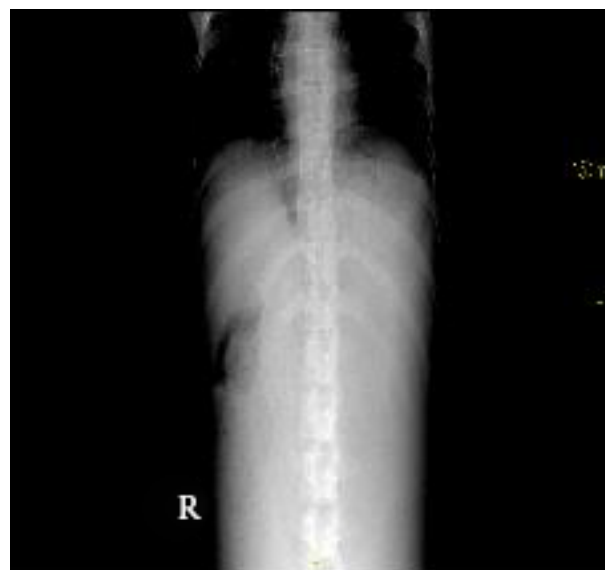
Vital signs at the time of arrival on the hospital included blood pressure 110/60 mmHg, pulse rate 72

beats/min, respiratory rate 20 breathes/min, and body temperature 36.5°C. The patient had an acute sickly appearance, with severe abdominal distension, rigidity, tenderness, and rebound tenderness, without palpable liver, spleen, kidney, and circumscribed mass. The bowel sounds reduced and the patient complained of nausea but did not vomit nor had fever. The clinical laboratory findings are shown in Table 1. There was a significantly expanded observation of stomach bubble in the abdominal radiograph but with no prominent intestinal gas. Electrocardiogram showed 110/min of sinus tachycardia. The patient did not show any improvement after taking digestive and laxative and thus visited the hospital emergency room where 17000 cc gastric lavage was conducted due to serious abdominal distensions. Great amount of undigested food was drained but still with no improvement. An endoscope treatment was conducted and decompression was carried out with a nasogastric tube due to lack of visual field. The abdominal distension and stomachache still did not get better even after conducting the decompression and abdominal computed tomography. Great amount of food was observed even to the third section of duodenum with small quantity of abdominal dropsy within the pelvic cavity. In addition, both pleural effusions were observed along with superior mesenteric artery syndrome from excessive gastric distention but with no fluid collection around pancreas despite of increasing value of lipase. Constant stomachache and difficulty in breathing of the patient after the abdominal computed tomography along with ardent will of the guardians for operation led to an operational treatment in the afternoon of the very same day after consultation among the surgical department. Stomach was cut vertically 5 cm long, careful of the extremely expanded stomach damage. There was a lot of blood from gastric atony and much amount of food was taken out by hand through the cut. Bleeding went on after removing the food and the incision was sealed together after hemostatic packing with cold saline and gel forms. Excessive bleeding from nasogastric tube and draining area after the operation continued with continuing unstable vital signs and unconsciousness. The massive bleeding led to no coagulation, with severe laboratory finding (Table 1). The disseminated intravascular coagulation (DIC) panel conducted on the second day at the hospital showed D-dimer > 1050 ng/mL, Fibrinogen, no coagulation, and Fibrin degradation product (FDP) test 52.9 $\mu\text{g/mL}$ while coagulation tests showed non-coagulation.

The above blood tests led to doubts on disseminated intravascular coagulation and vitamin K, packed red blood cells (PRC), and fresh frozen plasma (FFP) and Antithrombin III were injected. Symptoms of hypotension and pulmonary edema appeared while quantity of urine de-

creased. Sodium bicarbonate was injected for the correction of metabolic acidosis along with inotropics and diuretics. Despite active treatment for 3 days at the hospital, blood pressure did not increase and the heart rate decreased gradually, leading to cardiac arrest. Under the consent of guardians, the patient died without cardiopulmonary resuscitation.

Figure 1. Plain Abdominal Film on Admission



A supine plain abdominal film shows a huge air density ranging from the epigastrium to the pelvic cavity.

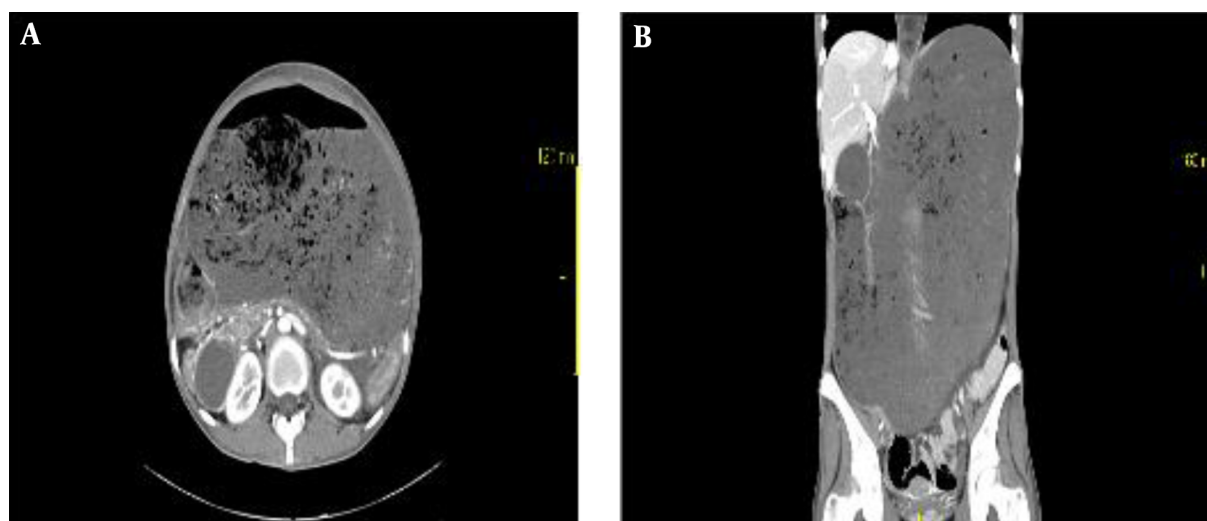
3. Discussion

Bulimia nervosa is a disorder with loss of control on eating and displaying maladaptive behaviors such as throwing up, taking laxatives, diuretics or doing extreme working out after binge eating to avoid weight gain (4). Repetitive binge eating and vomiting can show extreme changes in weight that is often along with depression and anxiety disorder. There are a few patients who visit the emergency room after eating huge amount of food due to experience of acute stomachache and vomiting and in these cases, bulimia nervosa needs to be recognized through psychological diagnosis and it should be treated with psychology behavior treatment and medicinal treatment (5). In addition, implementing protective care such as providing nutrition and correcting abnormal electrolytes and medical treatment may easily improve bulimia nervosa while with delayed diagnosis not only the improvement is delayed but also various complications

Table 1. Clinical Laboratory Findings

Variables	Patient Value on, 1 st Day	Patient Value on, 2 nd Day	Patient Value on, 3 rd Day	Unit	Measurement Device
White blood cells	7610	1380	2150	cells/ μ L	ADVIA [®] 2120i
Hemoglobin	13.4	5.3	7.6	g/dL	Same as above
Platelet	226000	24000	65000	cells/ μ L	Same as above
PT/aPTT	11.0/27.2	37.6/109	No coagulation	seconds	ACL TOP 500 CTS [®]
INR	0.95	5.1	No coagulation	seconds	Same as above
AST/ALT	13.3/9.94	508/205	1613/605	U/L	cobas 8000 [®]
BUN/Cr.	15.1/1.11	7.6/1.85	6.72/2.37	mg/dL	Same as above
Amylase/Lipase	181/793	253/820	274/802	U/L	Same as above

Abbreviations: AST/ALT, Aspartate Transaminase/Alanine Transaminase; BUN/Cr., Blood Urea Nitrogen/Creatinine; INR, International Normalized Ratio; PT/aPTT, Prothrombin Time/Activated Partial Thromboplastin Time.

Figure 2. Computed Tomography of the Abdomen Shows Massively Dilated Stomach Occupying the Abdominal Cavity Entirely from Diaphragm to Pelvis

The duodenum is dilated. There is a relatively small distance between the aorta and superior mesenteric vessels. In addition, there are a distended right colonic loop and small bowel loops reduced to the pelvic area and right lower abdominal quadrant.

such as acute gastric atony may take place that requires operational treatment (6). Acute gastric atony mainly comes from post-upper gastrointestinal surgery complications but may also stem from traumatic injury, chronic debilitating disease, diabetic ketoacidosis, drug addiction, and bulimia nervosa. On the other hand, acute gastric atony may happen when the duodenal transverse parts that cross the main artery or the spine are suppressed due to duodenum blocking. The clinical finding of acute gastric atony includes stomachache and abdominal distension while diseases that need clinical recognition due to constant vomiting include pyloric obstruction and small bowel obstruction (7). Differential diagnosis should include psycholog-

ical diseases like schizophrenia, depression, hysteric personality, inadequate personality disorder, and borderline personality disorder as well as medical diagnosis such as upper mesenteric artery occlusion, inflammatory bowel disease, chronic hepatitis, diabetes, hyperthyroidism, tuberculosis, and malignant tumor. The useful diagnostic test is a simple abdominal radiograph, which shows stomach bubbles on top of a huge air bubble and air-fluid levels. It also enables the use of gastric emptying test that utilizes symptoms, physical examination, and radioactive isotope (8). Complications include severe electrolyte disorder and endocrinologic complications, as well as acute pancreatitis, gastrointestinal bleeding, stomach or duodenal

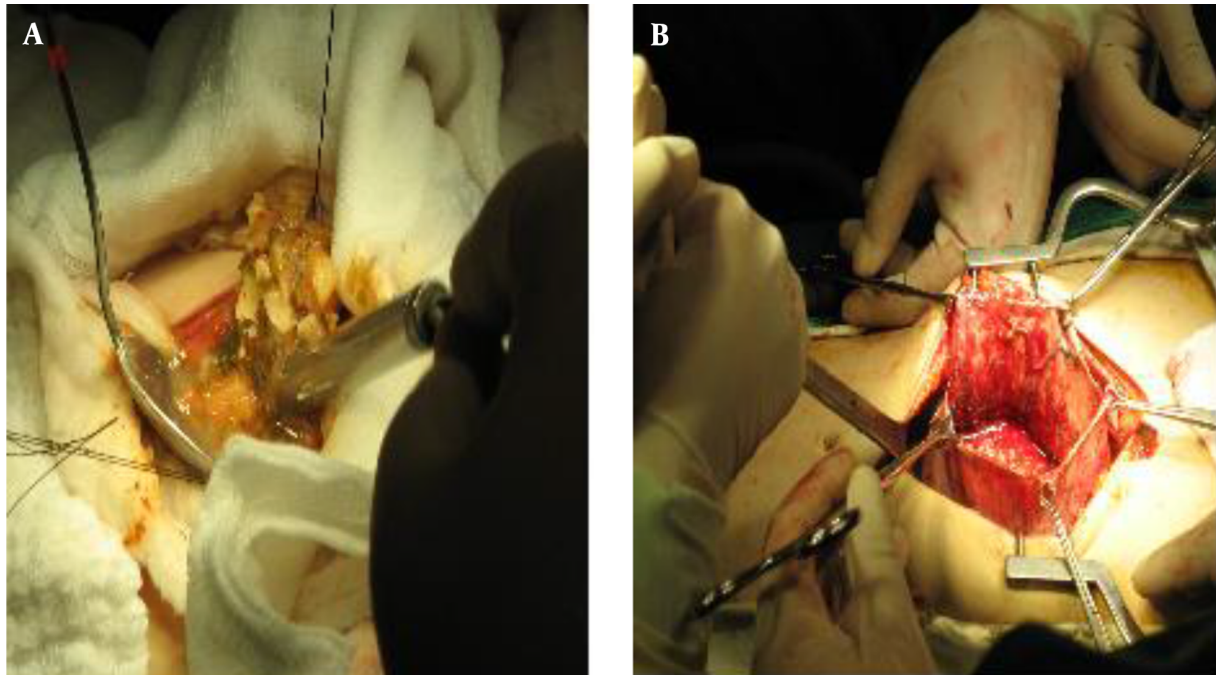


Figure 3. A, Pale Stomach, Much Food Material Shown on Stomach; B, Continuous Bleeding on Stomach Incision Site Was Found

perforation, and shock (9). Esophageal rupture, subcutaneous emphysema, and mediastinal pneumothorax rarely may take place. Oral food injection for anorexic patients may cause acute stomach dilatation, duodenal atresia, and acute pancreatitis while this case also showed test results that implicated acute pancreatitis with amylase 181U/L and lipase 793U/L but the abdomen computer tomography (CT) and operation findings showed no evidence of acute pancreatitis. For this specific case, the abdomen CT also did not find any significant abnormality on the pancreas and the surrounding areas and therefore, the increase in serum pancreatic enzyme level was unsure whether it was from pancreatic enzyme regurgitation in the pancreas or from subtle acute pancreatitis. Hypoglycemia due to not eating for a certain period may take place, and this is a faulty prognostic factor. Hypoglycemia often entails hypothermia, comatose, and infection and can be fatal.

In addition, cardiovascular abnormalities such as lung collapse, arrhythmia, orthostatic hypotension, and cardiac arrest as well as skin changes like scurvy, petechiae and purpura and peripheral neuropathy from chronic malnutrition may take place.

As for the treatment, it is important to prevent nasogastric tube insertions in case of acute gastric dilations and the treatment should include protective methods like appropriate fluid and electrolyte corrections (10, 11). Oper-

ational treatment is needed when treatment fails or gastric ischemia or gastric perforation is doubted. Nutrition rehabilitation comes first, and general non-oral nutrition intake as well as gradual correction on metabolic abnormalities is optimum. In addition, blood plasma and electrolyte concentration in urine as well as quantity of phosphorous acid and magnesium should be observed closely. Many medicines may be tried for medical treatment while the one with biggest effect is cyproheptadine (10, 11). Generally, early findings of the disease show good prognosis and acceptable treatment results for 30% - 50% of the patients in long run while there are variations. Death rate starts from 2% - 5% to a maximum of 18%. Frequency of binge eating, vomiting, suicide attempts, family history of mental disorder, and the use of laxatives and diuretics may be prognostic factors of bulimia nervosa (12-14). Causes of death include infection, metabolic catastrophe, heart failure, suicide, and starvation. Some die from complications of weight loss pills. Bulimia nervosa patients are frequent in emergency rooms but a case like this one is rare, with stomach expansion and gastric atony due to binge eating, failing protective treatment, and dying after operational treatment. This brings up an important aspect of treatment, particularly in treating those with eating disorders; one must be aware of the possibility of the development of the gastric atony due to severe gastric dilatation in such pa-

tients. In the case of future bulimia nervosa patients with gastric dilation who visit the emergency center, prevention and treatment of constant gastrointestinal bleeding, disseminated intravascular coagulopathy, pulmonary edema, and shocks should be focused on during operations in consideration of gastric atony.

Acknowledgments

This study was supported by research funds from Chosun University hospital in 2016

Footnotes

Declaration of Interest: None of the authors has conflicts of interest concerning commercial or financial involvements. No author is affiliated with an organization whose financial interests may be affected by material in the manuscript.

Patient's Consent: A document is available on patient written consent to this publication on request.

References

- Mendhekar DN, Mehta R, Srivastav PK. Bulimia nervosa. *Indian J Pediatr*. 2004;**71**(9):861-2. [PubMed: [15448397](#)].
- Polivy J, Herman CP. Causes of eating disorders. *Annu Rev Psychol*. 2002;**53**:187-213. doi: [10.1146/annurev.psych.53.100901.135103](#). [PubMed: [11752484](#)].
- Kaye WH, Klump KL, Frank GK, Strober M. Anorexia and bulimia nervosa. *Annu Rev Med*. 2000;**51**:299-313. doi: [10.1146/annurev.med.51.1.299](#). [PubMed: [10774466](#)].
- Nakano K, Nakajima H. [Definition and classification of eating disorders]. *Nihon Rinsho*. 2001;**59**(3):528-33. [PubMed: [11268603](#)].
- Shelley-Ummenhofer J, MacMillan PD. Cognitive-behavioural treatment for women who binge eat. *Can J Diet Pract Res*. 2007;**68**(3):139-42. doi: [10.3148/68.3.2007.139](#). [PubMed: [17784972](#)].
- Petribu K, Ribeiro ES, Oliveira FM, Braz CI, Gomes ML, Araujo DE, et al. [Binge eating disorder in a population of morbid obese candidates to bariatric surgery at the Oswaldo Cruz University Hospital in Recife, PE]. *Arq Bras Endocrinol Metabol*. 2006;**50**(5):901-8. doi: [10.1590/S0004-27302006000500011](#). [PubMed: [17160214](#)].
- Hasler WL. Gastroparesis: symptoms, evaluation, and treatment. *Gastroenterol Clin North Am*. 2007;**36**(3):619-47. doi: [10.1016/j.gtc.2007.07.004](#). [PubMed: [17950441](#)] ix.
- Maia Bosca M, Marti L, Minguez M. [Diagnostic and therapeutic approach to patients with gastroparesis]. *Gastroenterol Hepatol*. 2007;**30**(6):351-9. doi: [10.1157/13107570](#). [PubMed: [17662220](#)].
- Gualandi M. Eating Disorders and the Skin. Springer; 2013. pp. 17-30. Medical complications in eating disorders.
- Huang XD, Yang PR, Xu YZ, Yin Y, Tang QY, Zhang YH. [Etiology and treatment of eating disorders in adolescents: a report of 6 cases]. *Zhongguo Dang Dai Er Ke Za Zhi*. 2006;**8**(4):279-82. [PubMed: [16923356](#)].
- Ebeling H, Tapanainen P, Joutsenoja A, Koskinen M, Morin-Papunen L, Jarvi L, et al. A practice guideline for treatment of eating disorders in children and adolescents. *Ann Med*. 2003;**35**(7):488-501. doi: [10.1080/07853890310000727](#). [PubMed: [14649331](#)].
- Steinhausen HC. The outcome of anorexia nervosa in the 20th century. *Am J Psychiatry*. 2002;**159**(8):1284-93. doi: [10.1176/appi.ajp.159.8.1284](#). [PubMed: [12153817](#)].
- Lowe B, Zipfel S, Buchholz C, Dupont Y, Reas DL, Herzog W. Long-term outcome of anorexia nervosa in a prospective 21-year follow-up study. *Psychol Med*. 2001;**31**(5):881-90. doi: [10.1017/S003329170100407X](#). [PubMed: [11459385](#)].
- Herzog W, Deter HC, Fiehn W, Petzold E. Medical findings and predictors of long-term physical outcome in anorexia nervosa: a prospective, 12-year follow-up study. *Psychol Med*. 1997;**27**(2):269-79. doi: [10.1017/S0033291796004394](#). [PubMed: [9089820](#)].